

GIANT CELL TUMOR DI REGIO FEMUR DISTAL DEXTRA PADA LAKI-LAKI 25 TAHUN DENGAN HIV POSITIF (KASUS LANGKA)

GIANT CELL TUMOR OF THE RIGHT DISTAL FEMUR REGION IN A MALE 25 YEARS OLD WITH HIV POSITIVE (RARE CASE)

Muhammad Riyadli¹, Mujaddid Idulhaq², Pamudji Utomo²

¹Resident of Orthopaedic&Traumatology Faculty of Medicine Sebelas Maret University/Dr. Moewardi General Hospital/Prof. Dr. R. Soeharso Orthopaedic Hospital

²Staff Orthopaedic & Traumatology Faculty of Medicine Sebelas Maret University/Dr. Moewardi General Hospital/Prof. Dr. R. Soeharso Orthopaedic Hospital

Korespondensi: Muhammad Riyadli. Email: adiriyadli27@gmail.com

ABSTRACT

Giant cell tumor (GCT) with Human Immunodeficiency Virus (HIV) infection is a rare case. At present, few literatures reported about GCT with HIV positive patients and there are no effective treatments of this disease currently. The aim of this article is to report the change the surgical treatment from limb salvage (wide excision and endoprostheses) to another way limb salvage (wide excision and knee arthrodesis) to minimize risk and further complication. A case of male, 25 years old, with diagnosis GCT of the right distal femur with HIV positive. In this case we administered antiretroviral treatment (ARV) and planned to limb salvage surgery (wide excision and knee arthrodesis). We follow up this patient in the first 4 weeks. There were no complaints, good postoperative wounds, no signs of infection, and histopathological examination postoperative showed the positive results of a GCT. The conclusion the surgical treatment from limb salvage (wide excision and endoprostheses) to another way limb salvage (wide excision and knee arthrodesis) could minimize risk and further complication.

Keywords: Giant Cell Tumor, HIV, Limb Salvage Surgery, Wide Excision, Arthrodesis Knee

ABSTRAK

Giant Cell Tumor (GCT) disertai dengan infeksi Human Immunodeficiency Virus (HIV) merupakan kasus yang jarang terjadi. Pada saat ini hanya sedikit literatur yang melaporkan kejadian pasien GCT dengan HIV positif dan belum ada standar terapi yang efektif. Tujuan dari artikel ini adalah melaporkan penggantian penatalaksanaan operatif sebelumnya berupa limb salvage (eksisi luas dan pemasangan endoprosthesis) menjadi eksisi luas dan arthrodesis knee untuk meminimalisir risiko dan komplikasi lebih lanjut. Kasus seorang laki-laki usia 25 tahun dengan diagnosis GCT pada distal femur kanan dengan infeksi HIV positif. Pada kasus ini, terapi yang diberikan adalah Anti Retroviral (ARV) dan operatif dengan limb salvage (eksisi luas dan arthrodesis lutut). Follow up pasien ini pada 4 minggu pertama post operasi. Keluhan nyeri berkurang, luka operasi baik, tidak ada tanda infeksi dan pemeriksaan histopatologi menunjukkan hasil GCT. Kesimpulannya bahwa penatalaksanaan operatif sebelumnya berupa limb salvage (eksisi luas dan pemasangan endoprosthesis) menjadi eksisi luas dan arthrodesis knee dapat meminimalisir risiko dan komplikasi lebih lanjut.

Kata Kunci: Giant Cell Tumor, Hiv, Limb Salvage, Eksisiluas, Arthrodesis Lutut

How To Cite: Riyadli, M., Idulhaq, M., & Utomo, P. (2019). GIANT CELL TUMOR OF THE RIGHT DISTAL FEMUR REGION IN A MALE 25 YEARS OLD WITH HIV POSITIVE (RARE CASE). *Biomedika*, 11(2), 90-95. doi:<https://doi.org/10.23917/biomedika.v11i2.8279>

DOI: <https://doi.org/10.23917/biomedika.v11i2.8279>

BACKGROUND

Giant cell tumor (GCT) is a locally aggressive tumor with a low metastatic potential. The primary areas of involvement are the metaphyseal-epiphyseal junction of femoral condyles, tibial plateau, proximal humerus, and distal radius (Malawer *and* Sugarbaker, 2004). It's a kind of osteolytic tumor with high recurrence rate. The main component of this tumor are mononuclear cells and osteoclasts multiple nuclear cells (Sun *et al.*, 2017).

Human immunodeficiency virus (HIV) infection leads to a decrease of the count of CD4 T-cell, and the dysfunction of the macrophages and monocytes. It finally leads to immunodeficiency (Sun *et al.*, 2017). Loss of CD4 cells makes it hard for the body to fight off infections and certain HIV-related cancers (U.S. Department of Health and Human Services, 2019). At present, few literatures reported about HIV positive patients with GCT and there are no effective treatments of this disease currently (Sun *et al.*, 2017).

Treatment of GCT is surgical removal. Surgical choices of GCT are curettage, curettage with cytotoxic agents, curettage and a physical adjuvant, primary resection,

radiation therapy, and embolization (Malawer *and* Sugarbaker, 2004).

Antiretroviral therapy (ART) is the use of HIV medicines to treat HIV infection. People on ART take a combination of HIV medicines (called an HIV treatment regimen) every day. A main goal of ART is to reduce a person's viral load to an undetectable level. Overall, the benefits of HIV medicines far outweigh the risk of side effects (U.S. Department of Health and Human Services, 2019).

CASE REPORT

Male patient, 25 years old, with chief complaint lump on his right knee since 3months before admission. Patient complained about pain on his right knee region, no radiculating pain, the pain increase when standing and walking 1 year before. The pain getting worst, and then a lump appears 6 months ago. Patient cannot fully moving his right knee. The patient is also accompanied by additional complaints, including night pain, anorexia and loss of body weight. No family and tumor history.

The physical examination (Figure 1) showed Skin intact, no venectation, semicircular mass with size 25x20x15 cm, solid, clear margin, immobile, warm,

tenderness, with ROM of the knee 5-90°. Laboratory examination showed slight increase of ESR and Positive HIV rapid test with increase of CD4 count. Plain anterior-posterior and lateral radiograph of right knee (Figure 2) showed signs geographic lytic lesion, with cortical destruction and no pathological fracture. From FNAB that taken in previous hospital, the result is suspicious to Giant Cell Tumor, with differential diagnosis Chronic granulomatous infection.

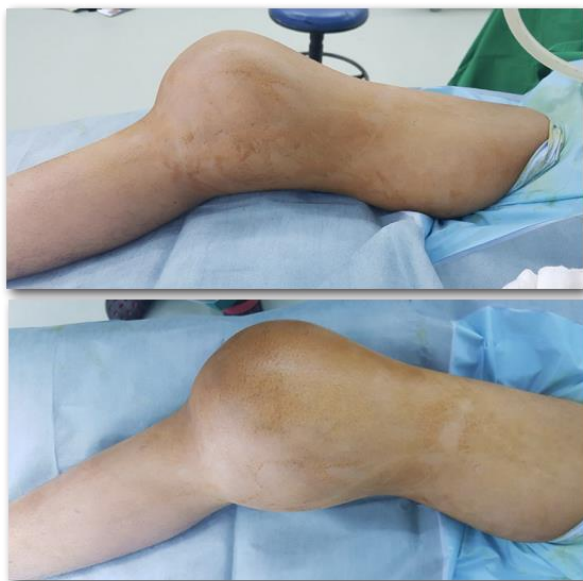


Figure 1. Preoperative clinical picture. The Lump at right knee of the patient

The physical examination (Figure 1) showed Skin intact, no venectation, semicircular mass with size 25x20x15 cm, solid, clear margin, immobile, warm, tenderness, with ROM of the knee 5-90°. Laboratory examination showed slight increase

of ESR and Positive HIV rapid test with increase of CD4 count. Plain anterior-posterior and lateral radiograph of right knee (Figure 2) showed signs geographic lytic lesion, with cortical destruction and no pathological fracture. From FNAB that taken in previous hospital, the result is suspicious to Giant Cell Tumor, with differential diagnosis Chronic granulomatous infection.

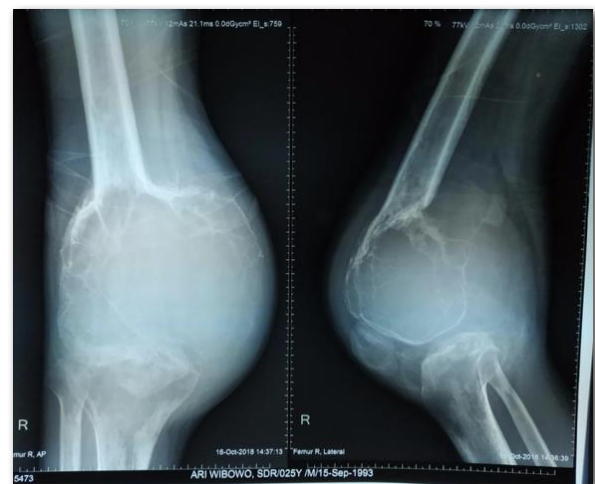


Figure 2. Plain Radiographs. Geographic Lytic Lesion of Right Distal Femur with Cortical Destruction

The patient was diagnosed with Primary Bone Tumor Right Distal Femur Region, Suspicious to Giant Cell Tumor, with HIV positive. The patient underwent a limb salvage surgery (wide excision and knee arthrodesis) and AntiRetroviral Therapy.

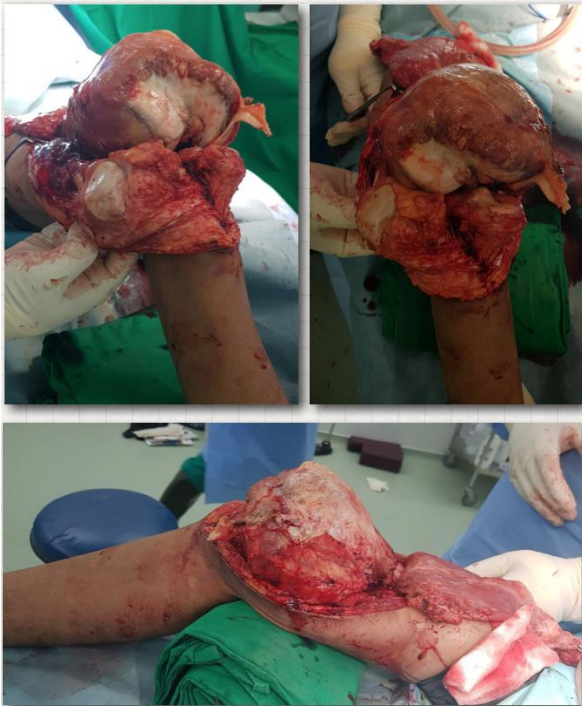

Figure 3. Durante operation

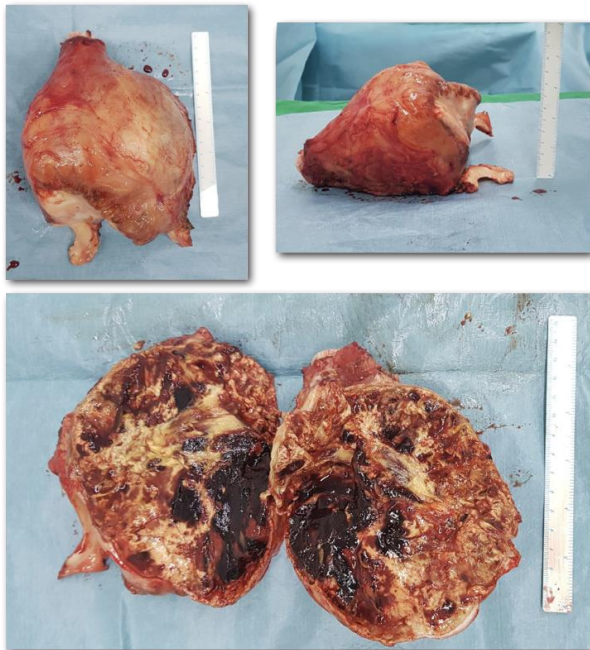


Figure 4. Excised Tumor

After operation procedure, the patient was motivated to do a rigorous post-operative rehabilitation program and continuous ARV therapy program. We follow up this patient in the first 4 weeks. there were no complaints, good postoperative wounds and no signs of

infection. The histopathological examination postoperative showed positive results of a giant cell tumor of the bone.

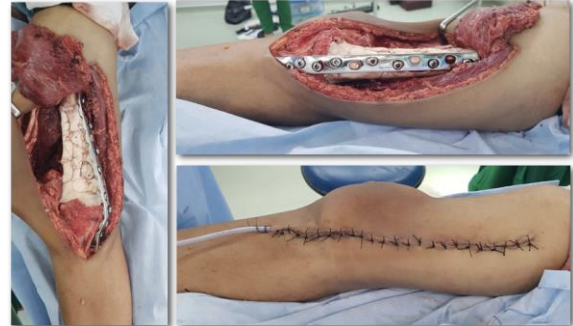

Figure 5. Arthrodesis with K-Nail, Broad plate and Bone cement

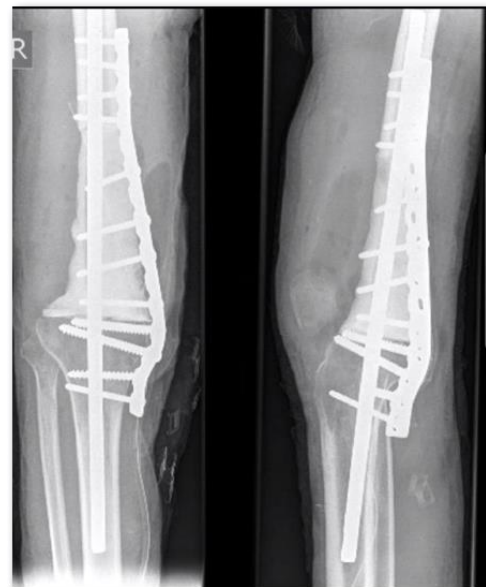

Figure 6. Postoperative X-Ray. Showed K-Nail and Broad Plate Fixation

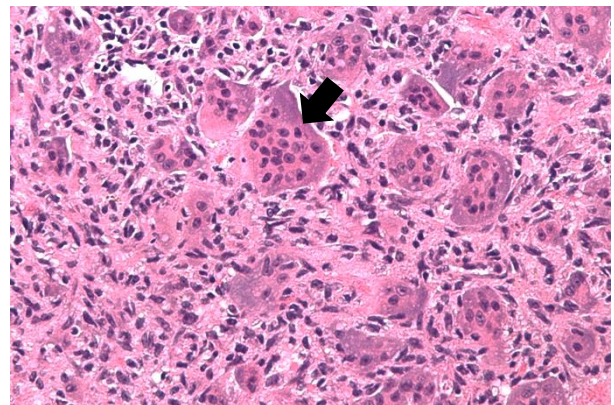


Figure 7. Postoperative Histopathology. Black Arrow Showed Multinucleus Giant Cell Tumor. Nuclei appears same as stromal cells.

DISCUSSION

There are few literatures reported about GCT patients with HIV positive, and no standard treatments in this case. Limb salvage surgery is the right choice for these cases, in addition to the use of ARV regimens for HIV infection. In these patients, limb salvage surgery can still be performed due to adequate tumor margins and good motor function (Puri, 2014).

There are a variety of reconstruction options after excision of bone tumors. Metallic prostheses (megaprotheses) is the best choice, providing both mobility and stability (Gosheger *et al.*, 2006). Although had beneficial, megaprotheses also has the risk of complications due to advanced techniques, long duration of operation, and greater risk of infection especially in immunocompromised patients (Puri, 2014).

Thus, surgeons chose to avoid these risks with the choice of limb salvage surgery in the form of tumor excision followed by knee arthrodesis. The general indication of arthrodesis are bone or tissue damage, weakness or loss of the knee extensor mechanism, inadequate ligamentous constraint, substantial bone loss or defects, osteosarcoma,

posttraumatic arthritis, arthrofibrosis, infection.

This technique can enable patients to ambulate without the use of assistive devices, facilitates mobility and allow patients to maintain independence (Lucas *et al.*, 2016). Although the patient's clinical outcome will not be as good as using megaprotheses, the risk of surgery can be reduced and the risk of amputation can be avoided.

CONCLUSION

GCT with a reactive HIV infection is a rare case. Because of the risk of immunodeficiency and few literatures reported about HIV positive patients with GCT and there are no effective treatments of this disease currently, we change the surgical treatment from limb salvage (wide excision and endoprotheses) to another way limb salvage (wide excision and arthrodesis knee) to minimize risk and further complication.

REFERENCES

- Gosheger, G., Gebert, C., Ahrens, H., Streitbuerger, A., Winkelmann, W., and Harges, J. 2006. Endoprosthetic Reconstruction in 250 patients with Sarcoma. *Clin Orthop Relat Res.*, 450:164-71.
- Lucas, E.M., Marais, N.C., and Desjardins, J.D., 2016. Knee Arthrodesis: Procedures and Perspectives in the US

from 1993 to 2011. *Springerplus*,
5(1):1606.

Malawer, M.M and Sugarbaker, P.H., 2004.
*Musculoskeletal Cancer Surgery,
Treatment of Sarcomas and Allied
Diseases*. New York: Kluwer
Academic Publisher.

Puri, A., 2014. Limb Salvage in
Musculoskeletal oncology:Recent
Advances. *Indian J. Plast Surg.*,
47:175-84.

Sun, S., Zhang, Q., Li, X. Wang, J.J., Zhang,
Y.S., Zhao, C.S., and Zhao, R.G. 2017.
Ultrasonic Scalpel Treatment for HIV
Positive Patients with Giant Cell
Tumor of Long Bone. *International
Journal of Clinical and Experimental
Medicine*, 10(4): 6853-60.

U.S. Department of Health and Human
Services, 2019. *Understanding
HIV/AIDS: HIV Treatment, The
Basics*. [Online]
Available at:
<http://www.aidsinfo.nih.gov>