

## **IMMEDIATE SURGICAL TREATMENT IN NEGLECTED OPEN LEFT SUPRACONDYLAR HUMERAL FRACTURE: A CASE REPORT**

### **PENATALAKSANAAN PEMBEDAHAN SEGERA PADA FRAKTUR TERBUKA HUMERUS SUPRACONDYLAR TERBAIKAN: SUATU LAPORAN KASUS**

**Tito Sumarwoto, Seti Aji Hadinoto, Hillan Akbar**

Department of Orthopaedic and Traumatology Medicine Faculty of Universitas Sebelas Maret Surakarta and Prof. DR. R. Soeharso Orthopaedic Hospital, Surakarta, Indonesia  
Korespondensi: dr. Tito Sumarwoto, Sp.OT (K). Email: [tito.ortho@staff.uns.ac.id](mailto:tito.ortho@staff.uns.ac.id)

#### **ABSTRACT**

*Supracondylar humeral fractures are the most common paediatric elbow fractures. However, open supracondylar humeral fractures are rarely found in children. In developing countries, delayed treatment is common, and patient can present to hospital as neglected case. The aim of this article is to report immediate surgical treatment in neglected case of open supracondylar humeral fracture. A case of 16-year-old boy who suffered from neglected open left supracondylar humeral fracture was reported. He had history of traffic accident 10 days before admission, and was treated by traditional bone setter. He has already undergone surgery by debridement and followed by an open reduction with cross K-wire internal fixation, and external support post operatively. The fracture has already reduced and fixated well postoperatively. Immediate surgical treatment of neglected open supracondylar humeral fractures is recommended to achieve the best reduction of the fractures and prevent the infection.*

**Key words:** Surgical Treatment; Neglected Case, Open Fracture, Supracondylar Humeral

#### **ABSTRAK**

*Fraktur humerus suprakondiler merupakan fraktur yang paling sering pada siku anak-anak. Namun, fraktur terbuka humerus suprakondiler jarang ditemukan pada anak-anak. Di negara berkembang, sering dijumpai penanganan yang tertunda, dan pasien bisa datang ke rumah sakit dalam keadaan sebagai kasus yang terabaikan. Tujuan dari artikel ini adalah untuk melaporkan penanganan pembedahan segera pada kasus fraktur terbuka humerus suprakondiler yang terabaikan. Dilaporkan seorang anak laki-laki berusia 16 tahun yang menderita fraktur humerus suprakondiler kiri yang terabaikan. Dia memiliki riwayat kecelakaan lalu lintas 10 hari sebelum datang ke rumah sakit, dan awalnya ditangani oleh dukun sangkal putung tradisional. Dia telah menjalani operasi dengan debridemen dan diikuti oleh reduksi terbuka dan pemasangan fiksasi internal menggunakan k-wire silang, dan pemasangan slab gips eksternal pasca operasi. Hasil pasca operasi menunjukkan bahwa fraktur tereduksi dan terfiksasi dengan baik. Penanganan pembedahan segera untuk fraktur terbuka humerus suprakondiler yang terabaikan direkomendasikan untuk mendapatkan reduksi terbaik dari fraktur dan mencegah infeksi.*

**Kata kunci:** Penanganan Pembedahan; Kasus Terabaikan, Fraktur Terbuka, Humerus Suprakondiler

**How to Cite:** Sumarwoto, T., Hadinoto, S., & Akbar, H. (2022). Immediate Surgical Treatment in Neglected Open Left Supracondylar Humeral Fracture: A Case Report. *Biomedika*, 14(2), 187-195. doi: <https://doi.org/10.23917/biomedika.v14i2.15186>

**DOI:** <https://doi.org/10.23917/biomedika.v14i2.15186>

## INTRODUCTION

Supracondylar humeral fractures are the most common paediatric elbow fractures (Abbott et al. 2014; Guo, Xie, and Su 2020). However, open supracondylar humeral fractures are rarely found in children, and the treatment protocol for open fractures is yet to be standardised (Al-Sadek et al., 2016). Displaced supracondylar humeral fractures are challenging injuries to treat and require technically difficult interventions for orthopaedic surgeons.

Supracondylar humeral fractures are usually treated in acute phase (Abbott et al. 2014). The best treatment method for displaced supracondylar humeral fractures is closed reduction and percutaneous Kirschner (K)-wire fixation (Guo et al. 2020). However, it cannot be done in neglected case because of callus growth. There are 2 treatment options in this situation. First start functional exercises 3 to 4 weeks after injury; the second is to perform open reduction and internal fixation with K-wires. There is currently no consensus represent the best treatment for neglected case. With the first option, concerns is the risk of cubitus varus as complication and for the second option, the question is whether surgery helps anatomic reduction easier or results in more complications compared to acute fracture (Guo et al. 2020).

In developing countries, the disorganized health insurance systems, some incorrect interventions by non-medical personnel, and other sociocultural or economic factors can be problems that significantly prolong the interval between the injury and the definitive treatment. These conditions cause late presentation of supracondylar humeral fracture becomes common for the orthopaedic surgeon (Abbott et al. 2014). Late presentation is defined as more than 2 days after injury or after 14 days of injury the patient presented for treatment, and objectively as the biological process of healing has already started with early callus formation and visible in x-rays but the fracture line is still visible (Rizk 2015; Shah et al. 2016; Sumarwoto et al. 2021).

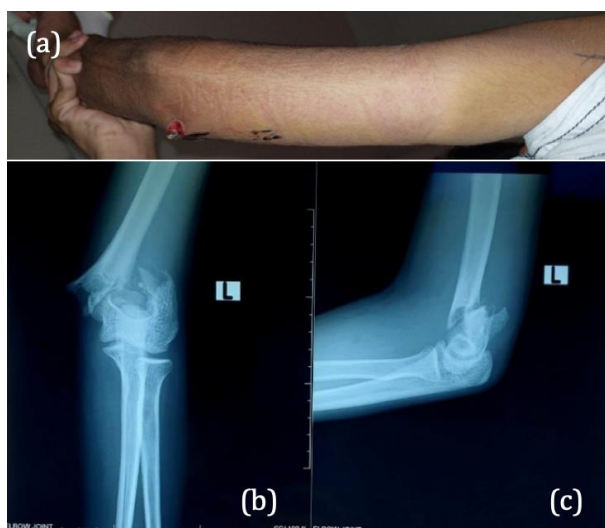
In this report, we present the case of a 16-year-old boy with a neglected open supracondylar humeral fracture and had underwent open reduction with internal fixation.

## CASE PRESENTATION

A 16-year-boy was brought to our emergency department with chief complaint of pain with open wound on the left elbow. The patient had history of traffic accident 10 days ago, and was treated by traditional bone setter. The next day, he was advised to take an X-ray examination and he went to regional hospital for the X-ray and

diagnosed with left open supracondylar humeral fracture. Then he came back to bone setter and was advised to be treated at hospital. The patients had never been experienced any accident or surgery before and had no history of systemic illness.

On physical examination, there was a 3 cm-wide wound with bone exposed on the medial aspect of the left elbow ([Figure 1a](#)). Valgus deformity was found on the left elbow. The range of motion of left elbow was limited due to pain. Due to delayed presentation to hospital, thus bleeding, contaminant, and swelling were no longer be found. Neurovascular examination showed no vascular or nerve injuries. Radiography examination performed at admission indicated a fracture at the left supracondylar humeral with severe extension displacement of the distal fragment fracture ([Figure 1b, 1c](#)).

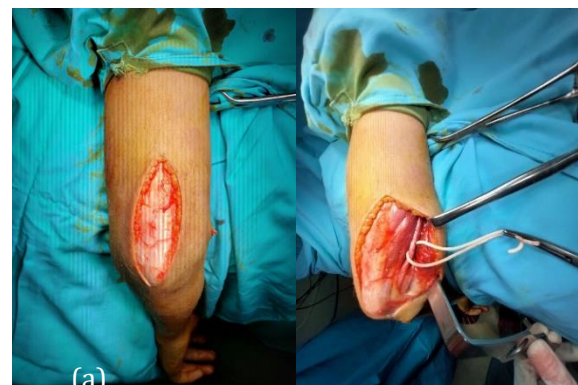

**Figure 1.** Preoperative condition. A 3-cm wound is seen on the medial aspect of the elbow with bone exposed(a).

Preoperative radiography on anteroposterior view (b) and lateral view (c) shows supracondylar humeral fracture with severe displacement.

The fracture was diagnosed as neglected open left supracondylar humeral fracture, extension type, Wilkin-modified Gartland III and Gustillo-Anderson III.

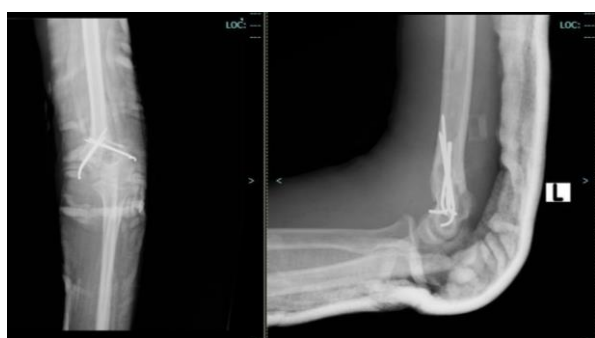The surgery was performed in operating theatre under general anesthesia by an Upper Limb, Hand, and Microsurgery Reconstruction surgeon. In lateral decubitus position, tourniquet was applied on the proximal of the fracture site. Firstly, thorough wound cleaning and debridement was done. Using posterior approach, a median posterior incision was made on the midline of the elbow ([Figure 2a](#)). The triceps muscle was splitted for exposing the fracture. During procedures, the ulnar nerve was isolated and preserved ([Figure 2b](#)).



**Figure 2.** A median posterior incision was made on the midline of the elbow (a) and ulnar nerve was isolated during procedures (b).

The fracture site was able to be identified precisely with pre-operative X-ray as guidance,

and we found minimal soft callus at the fracture site. Open reduction was done, and the fragment fracture was immobilized using K-wire 1.6 mm on lateral and medial condyle. Post operatively, the patient was externally supported by using back slab in flexion position and arm sling, and x-ray of the left elbow AP and lateral view was taken for evaluation ([Figure 3](#)).



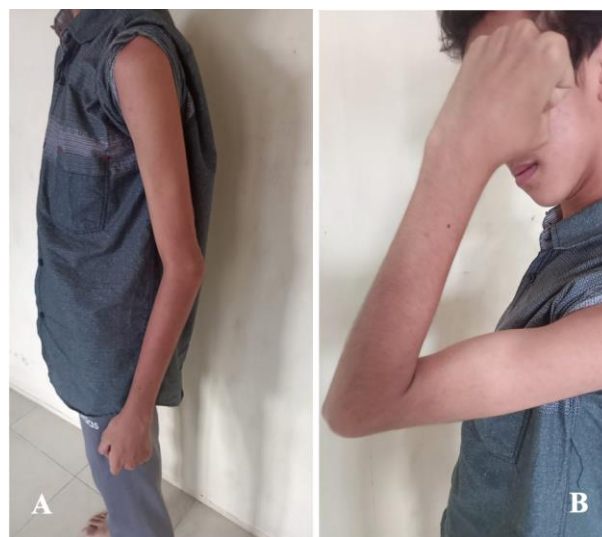**Figure 3.** Postoperative X-ray AP and lateral view of left elbow.

Baumann angle was  $72^\circ$  for radiological assessment in AP view and the anterior humeral line intersected the capitellum in lateral view, revealed the acceptable appearance in the X-ray. Antibiotic was continued up to 2x24 hours for prophylaxis and analgesics are given if there was still pain. The surgical wound healed well with no signs of infection after 2 weeks.

The patient encouraged to attempt early mobilization of the upper extremities joint. By two weeks after surgery the back slab for external support was broken in the elbow joint area and

expected the patient to flex and extend the elbow joint for the next two weeks as pain tolerated before finally removing it one month postoperatively.

In the two months after surgery, the range of motion were  $20^\circ$ - $150^\circ$  of flexion ([Figure 4](#)) and carrying angle was  $5^\circ$  measured with a goniometer, and according to Flynn's criteria for grading ([Table 1](#)) indicated satisfactory result.



**Figure 4.** Two months after surgery, the range of motion were  $20^\circ$ - $150^\circ$  of flexion.

## DISCUSSION

Supracondylar humeral fractures are the most common fracture around elbow in children, accounting for about 60% of all paediatric elbow fractures and 3% of all fractures (Abbott et al. 2014; Guo et al. 2020). In supracondylar humeral fractures, extension type fractures are more common (96-98%) than flexion type (Al-Sadek et al. 2016), including our case. Wilkins-modified

Gartland classification system divides extension type supracondylar humeral fractures into non-displaced, intact posterior cortex with or without rotation/translation, and complete displacement, either postero-medially or posterolaterally (Salter 1999).

The incidence of supracondylar humeral fractures in children has raised over the last decade. It is likely due children participate in high-energy activities in recent years (Teo et al. 2019), including motorcycle driving as presented in our case. According to Holt *et al.*, (Holt, Glass, and Shah 2018) children with open injuries are significantly older and more often male when compared with children with closed fractures. The study also stated about 9% of supracondylar humeral fracture was associated with polytrauma. These findings support the general belief that supracondylar humeral fractures in older children result from higher energy mechanisms and it is expected that the mechanism more often result in open injuries (Holt et al. 2018).

**Table 1. Flynn's Criteria For Grading (Shah et al. 2016)**

Result	Rating	Cosmetic factor (carrying angle loss/°)	Functional factor (motion loss/°)
Satisfactory	excellent	0 - 5	0 - 5
	good	5 - 10	5 - 10
Unsatisfactory	fair	10 - 15	10 - 15
	poor	> 15	> 15

In developing country, it is not uncommon to see patients with delayed presentation to the hospital after injury (Yi et al. 2020). The late case (neglected) is if the patient comes to the hospital roughly more than 2 days or more than 14 days after the fracture occurs. In our case the patient had already 10 days suffered from open supracondylar humeral fracture with minimal callus and the fracture line still exist. This condition can be caused by sociocultural belief and economic inability to access medical treatment. The lack of professional health workers or health facilities might also contribute. Problems related to poorly organized health insurance system and incorrect interventions by non-medical personnel can also prolong the interval between injury and immediate medical treatment (Sumarwoto et al. 2021).

Prof. Subroto Sapardan and Prof. Soelarto classified neglected fracture into 4 degrees based on the severity of the case as a result of the previous fracture treatment according to their research at RSCM and Fatmawati Hospital, Jakarta between February - April 1975. In this case above, it is included in the category of neglected third-degree fracture which showed delay causing permanent disability even after surgery. So patients who come early or late still require

surgery and the results may not be good (Reksoprodjo 2010).

Paediatric supracondylar humeral fracture is best treated in acute phase (Guo et al. 2020). The treatment of choice for displaced supracondylar humeral fractures is closed reduction and percutaneous fixation (Schmale et al. 2014). This technique should be done by professionals and there are risk of complications or partial failure. When closed reduction fails, open reduction should be considered (Rizk 2015). But, in neglected case, as callus has been appeared, closed reduction is no longer possible. There are two options of treatment in this condition, first start functional exercise 3 to 4 weeks after injury until consolidation phase and then the patient undergo osteotomy with the risk of *cubitus varus*, or second perform immediate open reduction and internal fixation (ORIF) (Guo et al. 2020; Sumarwoto et al. 2021).

Immediate treatment of neglected supracondylar humeral fracture could diminish the complications such as instability and arthritis. Delaying surgery have potentially increase compartment syndrome (Kwok et al. 2016; Putnam, Christophersen, and Adams 2017). But in neglected case there is a risk of failure to gain

satisfactory reduction due to be difficult to recognize the fragment fracture especially when the callus has already appeared at the fracture site. It explains that gaining the satisfactory reduction is challenging before fix the fragment fracture by k-wire (Sumarwoto et al. 2021; Vaquero-Picado, González-Morán, and Moraleda 2018). However, several studies have indicated that early surgery provides better result for supracondylar humeral fracture and reconstruction for neglected case is relatively more difficult. Many disadvantages include iatrogenic nerve injury, inability to visualize direct quality of the reduction, increasing radiation exposure, and requiring more experiences for the surgeon (Farrow et al. 2018; Li et al. 2020).

Although supracondylar humeral fracture is common in children, only 1% of these fractures present as open fractures (Holt et al. 2018; Lewine et al. 2018). Severe displacements and extensive vascular and/or nerve injuries usually accompany open supracondylar humeral fractures which cause the management becomes more complex. In addition, open fractures are often contaminated, increasing the risk of infection even after thorough irrigation and debridement. The treatment protocol for these open fractures have not been

standardised (Al-Sadek et al. 2016). Al-Sadek *et al* (Al-Sadek et al. 2016) states that the use of internal fixation in open supracondylar humeral fractures should be avoided because they are associated with an increased risk of infection, and recommends using external wrist fixator instead. But in other hand, Lewine *et al* (Lewine et al. 2018) uses open reduction with internal fixation plus irrigation, debridement and neurovascular decompression as their standard treatment for open supracondylar humeral fractures. Considering clean open wound and late presenting fracture in our case, we decided to do open reduction and internal fixation (ORIF) for our patient. Rizk (Rizk 2015) considers open surgery as the best treatment for late-presenting fractures because the need for ORIF increases as the time to surgery goes. The study also states there are low rate of complications associated with open reduction. In general, all of supracondylar humeral fractures should be reduced and stabilized timely. Immediate treatment of supracondylar humeral fracture can decrease risk of its complication, including compartment syndrome, instability, and arthritis (Sumarwoto et al. 2021). In other hand, not only delayed treatment has less favourable outcome (Guo et al. 2020), but also leads to an

increase in hospital stay length, resulting in additional costs (Yaokreh et al. 2012).

Some approaches are known in supracondylar humeral fracture surgery including anterior, medial, lateral and posterior approaches. It is recommended to use lateral approach in fracture with posteromedial displacement and medial approach in posterolateral displacement. In anterior approach, a transverse incision in the antecubital fossa is made and can be extended proximally or distally. The neurovascular structures can be easily accessed through this approach. The incidence of loss of fracture reduction is fewer compared to either a lateral or combined medial and lateral approach (Shenoy, Islam, and Puri 2020). In this patient, we use posterior approach which allows a visual assessment for proper reduction, ensures accurate wire positioning, and lowers the risk of iatrogenic ulnar nerve injury. But, this approach has disadvantages including higher risk of infection, unbecoming scars, and decreased range of elbow motion (Yaokreh et al. 2012).

There are several different configurations of K-wire placement can be used in supracondylar humeral fixation, from crossed pin to lateral pin configuration or several combinations. The use of

a medial pin is associated with an increased risk of ulnar nerve injury in 8% of patients compared to lateral only K-wires. Tethering effect within the cubital tunnel expected to be the reason rather than direct nerve injury. In this case, a medial pin is used, thereby some techniques for avoiding ulnar nerve injury should be used and meticulously documented. Fracture stability are greater when a crossed pin is used compared to divergent lateral pin (Shenoy et al. 2020).

## CONCLUSION

Immediate surgical treatment of neglected open supracondylar humeral fractures is recommended. Open surgical correction with proper technique by professional medical team should be performed for paediatric patients to achieve the best reduction of the fractures and prevent the infection.

## REFERENCES

- Abbott, M. D., Buchler, L., Loder, R. T., and Caltoun, C. B. 2014. Gartland Type III Supracondylar Humerus Fractures: Outcome and Complications as Related to Operative Timing and Pin Configuration. *Journal of Children's Orthopaedics*. 8(6). Pp= 473–77.
- Al-Sadek, T. A., Niklev, D., and Al-Sadek, A. 2016. Treatment of Pediatric Open Supracondylar Humerus Fractures: Case Report. *Macedonian Journal of Medical Sciences*. 4(4). Pp= 680–82.
- Farrow, L., A. D. Ablett, A. D., Mills, L., & Barker, S. 2018. Early versus Delayed Surgery for Paediatric Supracondylar Humeral Fractures in the Absence of Vascular Compromise. *The Bone & Joint Journal*. 100-B(12). Pp= 1535–41.
- Guo, M., Xie, Y., & Su, Y. 2020. Open Reduction of Neglected Supracondylar Humeral Fractures with Callus Formation in Children. *Journal of Pediatric Orthopaedics*. 40(8). Pp= 703–7.
- Holt, J. B., Glass, N. A., & Shah, A. S. 2018. Understanding the Epidemiology of Pediatric Supracondylar Humeral Fractures in the United States: Identifying Opportunities for Intervention. *Journal of Pediatric Orthopaedics*. 38(5). Pp= 245–51.
- Kwok, I. H. Y., Silk, Z. M., Quick, T. J., Sinisi, M., MacQuillan, A., and Fox, M. 2016. Nerve Injuries Associated with Supracondylar Fractures of the Humerus in Children: Our Experience in a Specialist Peripheral Nerve Injury Unit. *Bone and Joint Journal*. 98-B(6). Pp=851–56.
- Lewine, E., Kim, J. M., Miller, P. E., Waters, P. M., Mahan, S. T., Snyder, B., Hedequist, D., & Bae, D. S. 2018. Closed Versus Open Supracondylar Fractures of the Humerus in Children: A Comparison of Clinical and Radiographic Presentation and Results. *Journal of Pediatric Orthopaedics*. 38(2). Pp= 77–81.
- Li J, Rai S, Tang X, Ze R, Liu R, and Hong P. 2020. Surgical Management of Delayed Gartland Type III Supracondylar Humeral Fractures in Children: A Retrospective Comparison of Radial External Fixator and Crossed Pinning. *Medicine*. 99(10). P= 19449.
- Putnam, M. D., Christy M. C., and Julie, E. A. 2017. Pilot Report: Non-Operative Treatment of Mayo Type II Olecranon Fractures in Any-Age Adult Patient. *Shoulder and Elbow*. 9(4). Pp= 285–91.
- Reksoprodjo, S. 2010. *Kumpulan Kuliah Ilmu Bedah*. Tangerang Indonesia: Bina Rupa Aksara.
- Rizk, A.S. 2015. Triceps-Sparing Approach for Open Reduction and Internal Fixation of Neglected Displaced Supracondylar and Distal Humeral Fractures in Children. *Journal of Orthopaedics and Traumatology*. 16(2). Pp= 105–16.



- Salter, R.B. 1999. *Textbook of Disorder and Injuries of the Musculoskeletal System*. 3rd ed. Williams & Wilkins.
- Schmale, G. A., Mazor, S., Mercer, L. D., & Bompadre, V. 2014. Lack of Benefit of Physical Therapy on Function Following Supracondylar Humeral Fracture: A Randomized Controlled Trial. *Journal of Bone and Joint Surgery - American Volume*. 96(11). Pp= 944–50.
- Shah, R. K., Rijal, R., Kalawar, R.P.S., Shrestha, S.R., and Shah, N. K. 2016. Open Reduction and Internal Fixation of Displaced Supracondylar Fracture of Late Presentation in Children: A Preliminary Report. *Advances in Orthopedic Surgery*. Pp=1–6.
- Shenoy, P. M., Islam, A., and Puri, R. 2020. Current Management of Paediatric Supracondylar Fractures of the Humerus. *Cureus*. 12(5).
- Sumarwoto, T., Hadinoto, S. A., Pranandaru, H., Andhika, H., Rhatomy, S., and Utomo, P. 2021. Short-Term Follow-up of Early Reconstructive Surgery Management in Neglected Supracondylar Humeral Fractures. *Open Access Macedonian Journal of Medical Sciences*. 9. Pp= 24–28.
- Teo, T. L., Schaeffer, E. K., Habib, E., Cherukupalli, A., Cooper, A. P., Aroojis, A., Sankar, W. N., Upasani, V. V., Carsen, S., Mulpuri, K., and Reilly, C. 2019. Assessing the Reliability of the Modified Gartland Classification System for Extension-Type Supracondylar Humerus Fractures. *Journal of Children's Orthopaedics*. 13(6). Pp= 569–74.
- Vaquero-Picado, A., González-Morán, G., and Moraleda, L. 2018. Management of Supracondylar Fractures of the Humerus in Children. *EFORT Open Reviews*. 3(10). Pp= 526–40.
- Yaokreh, J. B., Odehouri-Koudou, T. H., Tembely, S., Dieth, A. G., Kouamé, D. B., Ouattara, O., and Dick, K. R. 2012. Delayed Treatment of Supracondylar Elbow Fractures in Children. *Orthopaedics and Traumatology: Surgery and Research* 98(7) Pp= 808–12.
- Yi, K. R., Leng, L. C., Kamaludin, N.A.A., Aziz, A.A., and Daud, K.N.M. 2020. Surgical Management of Paediatric Neglected Humeral Supracondylar Fracture: A Series of 3 Cases in 3 Years. *IJUM Medical Journal Malaysia* 18(2).