

ACUTE MEGAKARYOBLASTIC LEUKEMIA (AML-M7) IN 10-MONTH-OLD BABY BOY WITH DOWN SYNDROME

ACUTE MEGAKARYOBLASTIC LEUKEMIA (AML-M7) PADA BAYI LAKI-LAKI 10 BULAN DENGAN SINDROM DOWN

Tri Ratnaningsih¹, Aji Bagus Widyantara²

¹ Clinical Pathology Departement, Medicine Public Health and Nursing Faculty, Universitas Gadjah Mada

² Universitas 'Aisyiyah Yogyakarta

Korespondensi: Tri Ratnaningsih. Email: triratnaningsih@ugm.ac.id

ABSTRAK

Leukemia megakarioblastik akut (acute megakaryoblastic leukemia, AML-M7) merupakan subtype AML dengan mayoritas megakarioblas. Kejadian AML-M7 umumnya terjadi pada anak-anak dengan down syndrome. Bayi laki-laki berusia 10 bulan dengan down syndrome rujukan dari RSUD Muhammadiyah Yogyakarta datang dengan keterangan klinis prolonged fever suspek keganasan akut hematologi seri mieloid. Pemeriksaan tanda vital nadi 102x/menit, suhu 36,7°C pernafasan 30x/menit. Pemeriksaan fisik: berat badan 7,1 kg, tinggi badan 66,1 cm. Hepar teraba 6 cm bawah arcus costae, limpa Schuffner II. Pemeriksaan laboratorium didapatkan leukositosis, netropenia, dan trombositopenia. Pemeriksaan morfologi darah tepi disimpulkan gambaran suspek keganasan akut seri mieloid. Gambaran aspirasi sumsum tulang mendukung diagnosis leukemia megakarioblastik akut atau acute megakaryoblastic leukemia (AML-M7). Beberapa studi pada kelompok pediatrik menemukan sekitar setengah dari semua kasus AML-M7 terjadi pada anak-anak dengan down syndrome. Pada pemeriksaan fisik terdapat adanya organomegali. Pemeriksaan laboratorium didapatkan anemia, leukositosis, netropenia, dan trombositopenia. Pemeriksaan penunjang lain yang mendukung dalam penegakan diagnosis AML-M7 adalah morfologi darah tepi, aspirasi sumsum tulang, dan pengecatan sitokimiawi. Diagnosis acute megakaryoblastic leukemia (AML-M7) pada bayi dengan down syndrome. Diagnosis didasarkan gambaran klinis, anamnesis (alloanamnesa), pemeriksaan fisik, pemeriksaan laboratorium, dan pemeriksaan penunjang lainnya.

Kata Kunci: Acute megakaryoblastic Leukemia, AML-M7, Bayi, Syndrome Down

ABSTRACT

Acute megakaryoblastic Leukemia (AML-M7) is a subtype of AML where megakaryoblasts are the majority of the blasts. The incidence of AML-M7 is commonly seen in children with Down syndrome. A 10-month-old male baby with down syndrome, a referral from PKU Muhammadiyah General Hospital Yogyakarta, came with a prolonged fever suspected of acute hematological malignancy in the myeloid series. Vital signs examination of pulse rates: 102x / minute; temperature: 36.7°C; respiration: 30x / minute. On physical examination, the baby weighs 7.1 kgs, with a height of 66.1 cm. The palpable liver was 6 cm below the arcus rib, and the enlargement of the spleen was classified as Schuffner II. Laboratory tests explained leukocytosis, neutropenia, and thrombocytopenia. The peripheral blood morphology examination showed suspected acute malignancy with myeloid series. Bone marrow aspiration supported the diagnosis of acute megakaryoblastic Leukemia or acute megakaryoblastic Leukemia (AML-M7). Several studies in the pediatric group found that about half of all AML-M7 cases occurred in children with Down syndrome. On physical examination, there was organomegaly. Laboratory tests showed anemia, leukocytosis, neutropenia, and thrombocytopenia. Other supporting investigations in establishing the diagnosis of AMLM7 were peripheral blood morphology, bone marrow aspiration, and cytochemical staining. A diagnosis of acute megakaryoblastic Leukemia (AML-M7) in infants with Down syndrome. The diagnosis was based on clinical features, history (allo-anamnesis), physical examination, laboratory examination, and other supporting investigations.

Keywords: Acute megakaryoblastic leukemia, AML-M7, Baby, Down Syndrome

How To Cite: Ratnaningsih, T., & Widyantara, A. (2022). ACUTE MEGAKARYOBLASTIC LEUKEMIA (AML-M7) IN 10-MONTH-OLD BABY BOY WITH DOWN SYNDROME. *Biomedika*, 14(1), 90-98.
doi:<https://doi.org/10.23917/biomedika.v14i1.15062>

DOI: <https://doi.org/10.23917/biomedika.v14i1.15062>

BACKGROUND

Acute myelogenous Leukemia (AML) or acute myeloid Leukemia is a bone marrow malignancy due to hemopoietic precursor cells trapped in the early phase of its development. Acute megakaryoblastic leukemia (AML-M7) is a subtype of AML, where the majority of blasts are megakaryoblasts (Murtasyidah and Indrasari, 2019). Most subtypes of AML are distinguished from other blood disorders based on the number of blast cells in the bone marrow, which is more than 20%. AML classification according to The French-American-British (FAB) is M0 (undifferentiated Leukemia), M1 (myeloblastic without differentiation), M2 (myeloblastic with differentiation), M3 (promyelocytic), M4 (myelomonocytic; M4eo - myelomonocytic with eosinophilia), M5 (monoblastic leukemia; M5a monoblastic without differentiation; M5b - monocytic with differentiation), M6 (erythroleukemia), and M7 (megakaryoblastic leukemia). AML-M7 generally occurs in children with Down syndrome (Laurent and Kotecha, 2020). Diagnosis of AML M-7 is based on physical examination, peripheral blood morphology, bone marrow aspiration or bone marrow puncture, cytochemical staining,

immunophenotyping, and cytogenic analysis (Arber *et al.*, 2018).

CASE PRESENTATION

A 10-month-old male baby with Down syndrome, a referral from the PKU Muhammadiyah General Hospital Yogyakarta, was admitted to Dr. Sardjito General Hospital, Yogyakarta. According to patients' mother, the patient complains of prolonged fever for a week along with cough and cold before admitted to hospital. Then, the patient was taken to PKU Muhammadiyah Hospital Yogyakarta for laboratory examination. He had no family history of malignancy. On general physical examination, the child was *compos mentis* but looking weak and ill. His body length and body weights were 66.1 cm and 7.1 kgs, respectively. The vital sign examinations were normal, with the respiratory rate of 30 x/ minute, pulse rate of 102 x/ minute, and a body temperature of 36.7°C. His liver was palpated six cms below the rib arc, and the spleen was enlarged, classified as Schuffner II. Furthermore, several additional examinations were done to support the

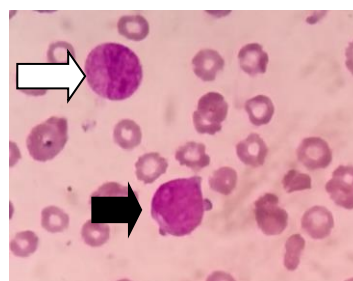
diagnosis. A laboratory test was drawn and showed leukocytosis with a low platelets count (Table 1). Complete blood count test showing level of hemoglobin (Hb) was 7.3 g / dL; leukocytes count was $29.6 \times 10^3 / \mu\text{L}$; platelets count was $93,000 / \mu\text{L}$, and suspected for acute malignancy in myeloid series from morphological examination of the peripheral blood result. The patient was advised to be hospitalized. The day he was admitted to the hospital, the patient was still feverish and looks weak. The patient was given D5 + $\frac{1}{4}$ NS rehydration therapy, Ceftazidine injection 2x350mg, 100 cc PRC transfusion. Then the patient was referred to the Dr. Sardjito General Hospital, Yogyakarta.

In peripheral blood morphology, blasts with myeloid series and megakaryoblast-like cells (4%) were seen (Fig.1a). At the same time, in bone marrow aspiration, we found hypercellular density, 60% of megakaryoblasts appeared with a high ratio of nucleus to cytoplasmic accompanied by cytoplasmic blebbing cytoplasmic projection as well as dysmegakaryopoiesis (multiple separated nuclei of megakaryocyte) (Fig.1c).

Table 1. Hematology Test

Parameters	Value	Reference	l.c
Haemoglobin	11.2	9.6-15.6 g/dL	
Red blood cell	3.66	$3.40-5.20 \times 10^6 / \mu\text{L}$	
Leukocytes	60.62	5.50- $17.50 \times 10^3 / \mu\text{L}$	
Platelets	49	$150-450 \times 10^3 / \mu\text{L}$	
Manual differential counting:			
Lymphoblast-like cell	3%		
Lymphocyte	2%		
Megakaryoblastlike-cell	4%		
Monoblast	16%		
Promonocyte	1%		
Myeloblast	56%		
Myelocyte	2%		
Metamyelocyte	2%		
Stab	1%		
Neutrophils	13%		

1a.



1b.

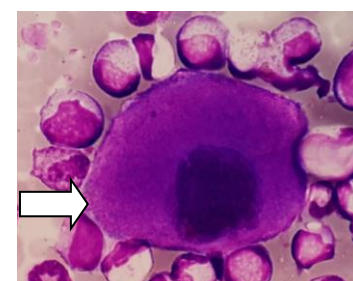
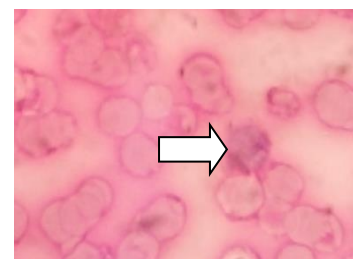


Figure 1. Myeloblast-like cell (white arrow) and megakaryoblast-like cell (black arrow) are seen in peripheral blood morphology (a). Megakaryoblasts appeared in blood marrow aspiration using Periodic Acid Shift (PAS) staining (b). Dysplasia megakaryocyte (c).

Nucleated cell counts examination revealed 15% of myeloblasts, 1% of myelocytes, 1% of metamyelocytes, 2% of stabs, 11% of segments, 1% of monoblasts, 1% of monocytes, and 8% of lymphocytes. Periodic Acid Shift (PAS) staining expressed a positive result of coarse granules on bleb and pseudopod/cytoplasmic projection (Fig 1.b), whereas Sudan Black B staining supported the findings of megakaryoblasts. This patient was clinically diagnosed with Down syndrome, leukocytosis, and prolonged fever in hematological malignancy suspected AML-M7. In patients with acute hematologic malignancy, monitoring and evaluating routine blood and other organs function are performed. Moreover, to confirm the diagnosis of AML-M7, bone immunophenotyping is necessary.

The day of admission to Sardjito Hospital, the patient received chemotherapy with the anti-leukemic agents consisting of Daunorubicin 18mg/m²/day IV in 6 hours, Cytarabine 36 mg/m²/dose IV pushed 2x/day and Triple Intrathecal drugs (Methotrexate 6mg, Hydrocortisone, Ara-C 15 mg). One day, the patient had a fever after chemotherapy and had been given an injection of antibiotics. The patient was treated with ceftazidime and

gentamicine, then changed to ciprofloxacin and ampicillin and meropenem for up to 14 days. During the 25-day hospital stay, the patient improved and was discharged home. The therapy given at the time of discharge was zinc 20 mg/24 hours, cotrimoxazole 360 mg/8 hours, ketoconazole 50 mg/24 hours and control continued chemotherapy. Two days after returning home, the patient was again treated at the Sardjito Hospital in Yogyakarta. The patient entered with complaints of sudden high fever, runny nose and red spots on the feet and hands. Then the patient was diagnosed with febrile neutropenia and treated for 3 days with ampicillin injection therapy 170 mg/6 hours and ciprofloxacin injection therapy 35mg/12 hours. The chemotherapy that the patient underwent was completed in September 2016. After the chemotherapy was completed, the patient was hospitalized several times with a different diagnosis instead of AML.

DISCUSSION

Acute megakaryoblastic leukemia (AML-M7) is a rare bone marrow malignancy, which involves the rapid proliferation of megakaryoblasts (early megakaryocyte forms). Distribution of AML-M7 in early childhood (<3

years) around 3-10 %. Several studies in the pediatric field found that about half of all AML-M7 cases occurred in children with Down syndrome (Taub *et al.*, 2017). In children, acute megakaryoblastic leukemia (AMKL) (FAB classification AML M7) is an unique AML subtype. Malignant megakaryoblasts are frequently accompanied by bone marrow fibrosis, which can make diagnosis difficult (Gruber and Downing, 2015). There are two forms of AMKL: Down syndrome (DS) and non-Down syndrome AMKL (Quessada *et al.*, 2021).

Failure of bone marrow cell maturation in the early phase of development is the pathophysiology that underlies AML. The mechanism is still being investigated, but in some cases, this involves activating abnormal genes through chromosome translocation and other genetic abnormalities. These inherited and acquired conditions can induce leukemogenesis through mechanisms that include chromosomal imbalances or instabilities, defects in DNA repair, altered cytokine receptor or signal transduction pathway activation, and altered protein synthesis.

AML is a diverse category of myeloid leukemias that develop from clones of haematopoietic stem and progenitor cells (HSPCs) and myeloid lineage precursors with genetic abnormalities that impair cell proliferation and differentiation. Most cases of myeloid leukaemia of Down syndrome (ML-DS) phenotypically resemble acute megakaryoblastic leukaemia (AMKL), a rare subtype of AML in which mutations impair megakaryocytic development. ML-DS has a characteristic multi-step progression that is invariably preceded by a pre-leukemic syndrome known as transitory aberrant myelopoiesis (TAM) or transient myeloproliferative disorder (TMD) (de Castro *et al.*, 2021).

Mutations in the haematopoietic transcription factor GATA1 are found in all TMD cases. The disease affects around 10% of DS newborns and is usually identified two months after birth by finding a large number of immature blasts in the circulating blood. However, the existence of GATA1 mutations in up to 30% of DS

babies suggests that another 20% of TMD cases are undiscovered or silent. TMD can cause severe symptoms such thrombocytopenia, leukocytosis, anemia, lymphocytosis, and liver failure in children, and roughly 20% of patients die (de Castro *et al.*, 2021).

The molecular mechanisms behind the transition from TMD to ML-DS are still unknown. In addition to GATA1 mutations, large-scale sequencing investigations have revealed the most common mutations acquired in ML-DS. Surprisingly, mutations in cohesin or CTCF, the two main drivers of three-dimensional (3D) genome folding, are found in over half of the cases. This high frequency is surprising, especially considering CTCF is infrequently mutated in AML or other myeloid malignancies. Furthermore, chromatin regulators such EZH2 are mutated more frequently in ML-DS than in AML. Receptors and components of the Janus kinase-signal transduction and activator of transcription (JAK-STAT) signaling cascade, as well as

the RAS pathway, are the most common sites for signaling pathway mutations. In DS, these mutations may conflict with or cooperate with altered signaling pathways. The relationship between the three genetic factors that make up this disease—trisomy 21, GATA1 mutations, and secondary mutations—is, however, poorly known in general (de Castro *et al.*, 2021).

Clinical symptoms in AML patients result from bone marrow failure and infiltration of leukemic cells in various organs. Patients can experience splenomegaly, gingivitis, and other symptoms. Specific examination of the patient obtained a palpable liver, 6 cm below the rib arc, and an enlarged spleen, classified as Schuffner II. The duration of the disease varies in some patients, especially children, who experience acute symptoms from several days to 1 or 2 weeks, while other patients experience a longer duration of the disease, persist for months⁴. The results of a complete blood count showed, Hb: 11.2 g / dl; leukocyte count: 60.62 x 10³ / μL; and platelets: 49,000/μL. The presence of anemia, neutropenia, and thrombocytopenia is caused by a failure of bone marrow in maintaining its function. The most common

symptom of anemia is fatigue. Neutropenia causes patients to be susceptible to infection. Gum bleeding and ecchymosis are manifestations of thrombocytopenia. A life-threatening event may happen in patients if bleeding occurs in the lungs, gastrointestinal tract, and central nervous system. In addition to complete blood count and physical examination, other tests that should also be carried out to help confirm the diagnosis are peripheral blood morphology, bone marrow puncture (BMP), and cytochemical staining (Gandhi and Patel, 2019). The peripheral blood morphology examination explained a suspicion of acute malignancy series of myeloid while bone marrow puncture (BMP) support the diagnosis of acute megakaryoblastic leukemia or acute megakaryoblastic leukemia (AML-M7).

Children with Down syndrome (DS) have a 150-fold higher risk of AML than children without DS, and AMKL is the most common AML subtype. It is caused by a GATA1 mutation that causes temporary abnormal myelopoiesis (TAM) in roughly 25% of neonates, which can progress to full-blown AMKL in 10% of patients before the age of five years (Roberts and Izraeli, 2014; Gruber and

Downing, 2015; Labuhn *et al.*, 2019). Because DS-AMKL blasts contain megakaryoblastic and erythroid characteristics, it is classified by the WHO as "myeloid leukemia associated with Down syndrome" (ML-DS), which responds well to chemotherapy and can be cured with lower dosages. In one study, acquired cytogenetic abnormalities (mostly trisomy 8, acquisition of additional chromosome 21, and 1q gain) had no effect on the outcome, whereas in another, trisomy 8 was associated with a poor prognosis (Taub *et al.*, 2017; Uffmann *et al.*, 2017).

Within the first four years of life, about 20% of TAM patients develop AMKL, which may be preceded by a myelodysplastic-like condition. Because finer differentiation has no prognostic or therapeutic value, the World Health Organization's 2008 classification system introduces the category "myeloid leukemia associated with DS" (herein referred to as DS-AMKL) to encompass both myelodysplastic and leukemic manifestations regardless of blast percentage. The median age of onset is two

years, which is younger than in non-DS-AMKL patients. Low WBC counts, cytopenia, organomegaly, increasing marrow fibrosis, and other cytogenetic abnormalities are common symptoms in patients (monosomy 7, trisomy 8). Blasts in DS-AMKL resemble TAM blasts in terms of morphology and immunophenotype. Patients with DS-AMKL have a good prognosis, with an overall survival rate of 80% after three years. This high response rate can be attributed in part to megakaryoblasts' increased chemosensitivity to cytarabine. The cytidine deaminase gene is involved in cytarabine catabolism, and its expression is reduced in DS, possibly leading to reduced intracellular drug metabolism and greater therapeutic efficacy (Bomberly and Vergilio, 2014).

CONCLUSION

Based on clinical features, history, physical examination, laboratory tests, and other investigations, the patient was diagnosed with acute megakaryoblast leukemia or acute megakaryoblast leukemia (AML-M7) in infants with Down syndrome.

Acknowledgments

We would like to thank the patient who has participated in this study.

REFERENCES

- Arber, D. A. Orazi A, Hasserjian R, Thiele J, Borowitz MJ, Le Beau MM, Bloomfield CD, Cazzola M, and Vardiman JW. 2018. The 2016 revision to the World Health Organization classification of myeloid neoplasms and acute leukemia. *Blood*. 127(20). Pp: 2391–406. doi: 10.1182/blood-2016-03-643544.
- Bomberly, M. and Vergilio, J. A. 2014. Transient Abnormal Myelopoiesis in Neonates: GATA Get the Diagnosis. *Archives of Pathology & Laboratory Medicine*. 138(10). Pp: 1302–6. doi: 10.5858/arpa.2014-0304-CC.
- de Castro, C. P. M., Cadefau, M. and Cuartero, S. 2021. The Mutational Landscape of Myeloid Leukaemia in Down Syndrome. *Cancers*. 13(16). p. 4144. doi: 10.3390/cancers13164144.
- Gandhi, D. and Patel, J. 2019. Acute megakaryocytic leukemia (M7) in a newborn with down syndrome. *IAIM*. 6(6). Pp: 128–31.
- Gruber, T. A. and Downing, J. R. 2015. The biology of pediatric acute megakaryoblastic leukemia. *Blood*. 126(8). doi: 10.1182/blood-2015-05-567859.
- Labuhn, M., Perkins K, Matzk S, Varghese L, Garnett C, Papaemmanuil E, Metzner M, Kennedy A, Amstislavskiy V, Risch T,

- Bhayadia R, Samulowski D, Hernandez DC, Stoilova B, Iotchkova V, Oppermann U, Scheer C, Yoshida K, Schwarzer A, Taub JW, Crispino JD, Weiss MJ, Hayashi Y, Taga T, Ito E, Ogawa S, Reinhardt D, Yaspo ML, Campbell PJ, Roberts I, Constantinescu SN, Vyas P, Heckl D, and Klusmann JH. 2019. Mechanisms of Progression of Myeloid Preleukemia to Transformed Myeloid Leukemia in Children with Down Syndrome. *Cancer Cell*. 36(2). Pp: 123-38. doi: 10.1016/j.ccell.2019.06.007.
- Laurent, A. P. and Kotecha, R. S. 2020. Gain of chromosome 21 in hematological malignancies: lessons from studying leukemia in children with Down syndrome. *Leukemia*. Pp: 1984-99. doi: 10.1038/s41375-020-0854-5.
- Quessada, J. Cucuini W, Saultier P, Loosveld M, Harrison CJ, and Lafage-Pochitaloff M. 2021. Cytogenetics of Pediatric Acute Myeloid Leukemia: A Review of the Current Knowledge. *Genes*. 12(6). p. 924. doi: 10.3390/genes12060924.
- Roberts, I. and Izraeli, S. 2014. Haematopoietic development and leukaemia in Down syndrome. *British Journal of Haematology*. 167(5). Pp: 587-99. doi: 10.1111/bjh.13096.
- Taub, J. W. Berman JN, Hitzler JK, Sorrell AD, Lacayo NJ, Mast K, Head D, Raimondi S, Hirsch B, Ge Y, Gerbing RB, Wang YC, Alonzo TA, Campana D, Coustan-Smith E, Mathew P, and Gams AS. 2017. Improved outcomes for myeloid leukemia of Down syndrome: a report from the Children ' s Oncology Group AAML0431 trial. *Blood*. 129 (25). Pp: 3304-13. doi: 10.1182/blood-2017-01-764324.The.
- Uffmann, M. Rasche M, Zimmermann M, von Neuhoff C, Creutzig U, Dworzak M, Scheffers L, Hasle H, Zwaan CM, Reinhardt D, and Klusmann JH. 2017. Therapy reduction in patients with Down syndrome and myeloid leukemia: the international ML-DS 2006 trial. *Blood*. 129 (25). Pp: 3314-21. doi: 10.1182/blood-2017-01-765057.